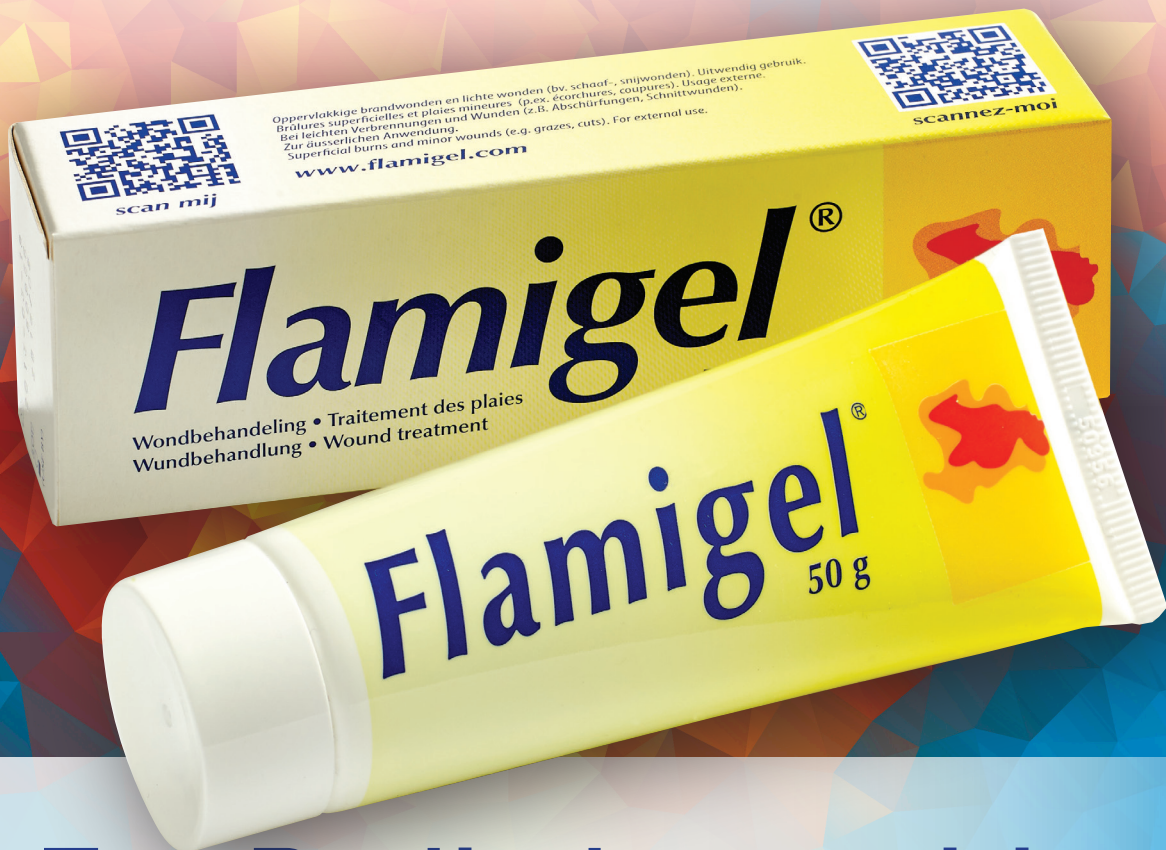



For Radiodermatitis

Soothing and healing with **Flamigel**^{4,5}

 **EBOS**
HEALTHCARE

ESSENTIAL TO HEALTH

Clinically proven treatment for radiodermatitis^{1,2}

Radiodermatitis occurs in 95% of patients after radiotherapy.¹

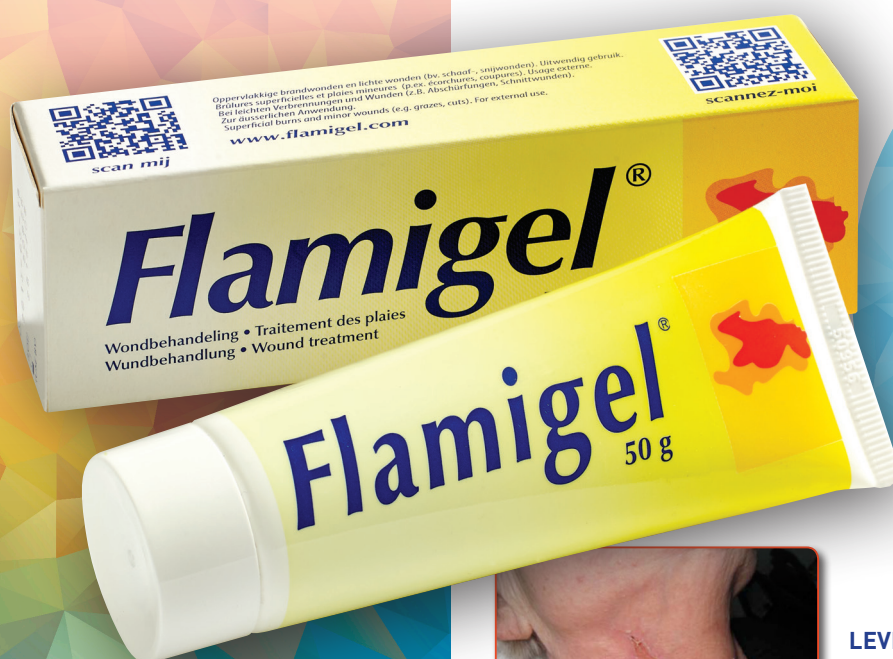The skin can:

- Become red
- Feel painful
- Itch
- Have a warm or burning sensation

Patient benefits:

- Flamigel® delays and reduces occurrence of radiotherapy-induced moist desquamation^{1,2}
- Cooling effect eases the pain and irritation^{2,3}
- Easy to use
- Easy to remove
- No bandage required
- Does not stain clothes
- Aids recovery from the delayed skin reaction to radiotherapy^{1,2}

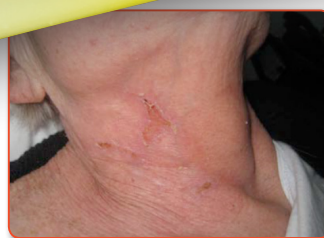Radiodermatitis can occur 1 to 2 weeks after the radiation treatment.



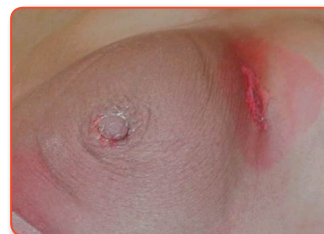Radiodermatitis can cause the dose of radiation to be reduced or for the treatment to be stopped completely.

Cools and soothes the pain.⁵

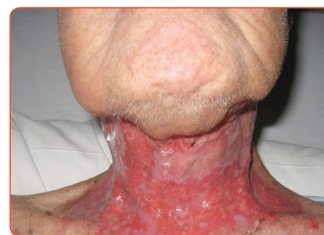Aids the skin's natural recovery.^{2,3}



LEVEL 1:
Light erythema, dry desquamation.

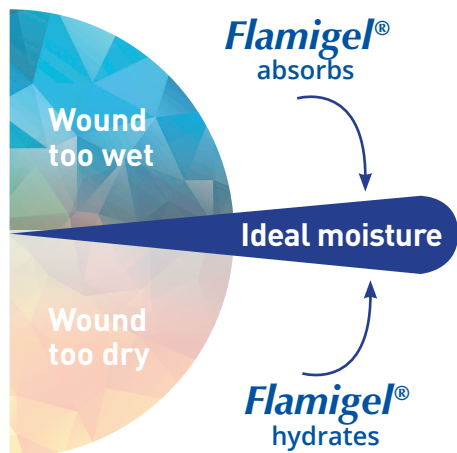


LEVEL 2:
Moderate to severe erythema, irregular moist desquamation, limited to the folds of the skin



LEVEL 3:
Emerging moist desquamation, not limited to the folds of the skin.

Recommended for moist and dry wounds

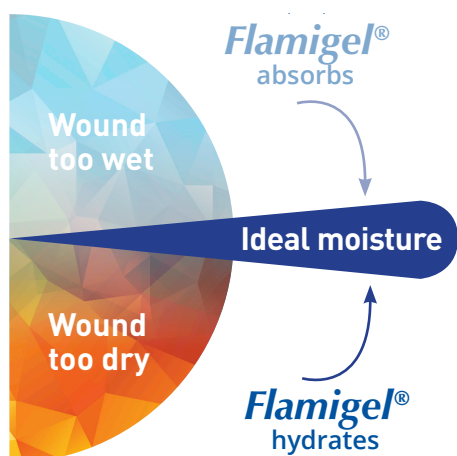


IN MOIST WOUNDS

Hydrocolloids absorb exudate

Ideal wound moisture

Accelerates wound healing



IN DRY WOUNDS

Hydrogel absorbs exudate

Ideal wound moisture

Accelerates wound healing

Efficacy of a hydroactive colloid gel versus historical controls for the prevention of radiotherapy-induced moist desquamation in breast cancer patients.

Censabella S. et al. Eur J Oncol Nursing 2017; 29: 1-7

OBJECTIVE:

To reduce and delay radiation-induced moist desquamation in breast cancer patients.

METHOD:

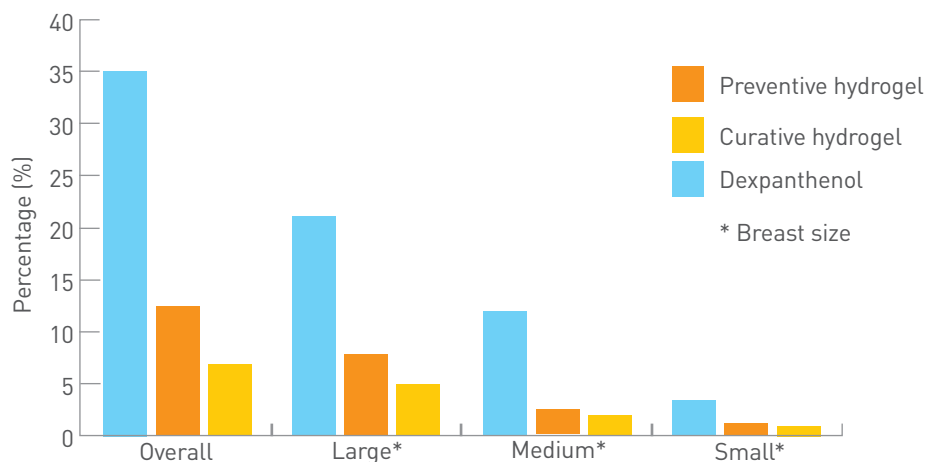


All patients were administered equal doses of radiation.

FINAL STUDY:

Incidence of radiotherapy-induced moist desquamation.

Time until the occurrence of moist desquamation.



RESULTS:

Flamigel® brings a significant improvement, both preventively and curatively, in the occurrence of radiotherapy-induced moist desquamation compared to dexpantenol.

CONCLUSION:

Using **Flamigel®** from the start of the radiotherapy treatment compared to dexpantenol results in:

- later occurrence of moist desquamation,
- less incidence of moist desquamation,
- Use of 1 product during radiotherapy is much easier for patients than the use of 2 different products.

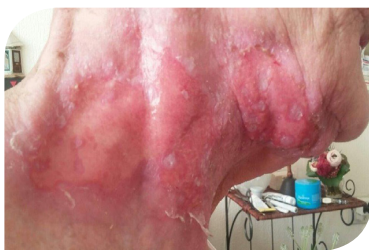Treatment of radiation damage with Flamigel® and Flaminal® Hydro

Henny Hooiman, Nurse, Careyn, Maasland, Netherlands

BACKGROUND:

84-year-old woman with a carcinoma in the mouth. Radiation damage to the neck following 33 treatments.

Patient was treated with Silver sulfadiazine (applied thickly on the neck) and Cutisorb®5 plus a fixing bandage. The wound area worsened and application of the Silver sulfadiazine was very painful. A new wound care approach began on 3 April after discussion with the radiologist at the Erasmus MC.

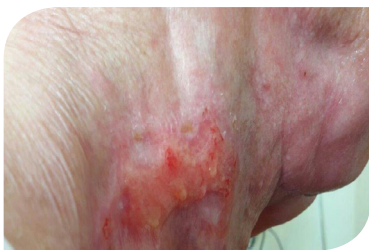

DAY 1: INTAKE

Wound was painful. The exudate had no odour. The colour of the exudate was yellow and green.

T: 100% red
I: Painful, swollen, pus
M: Yellow/green and moist
E: Scabs

Administration: 1x per day change of bandage and rinse. Flamigel® 0.5 cm cover with Mepitel® One and absorbent bandage.

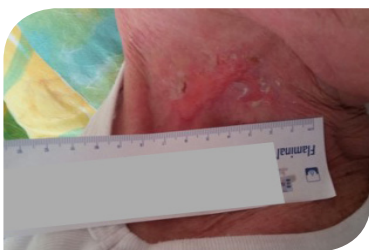

DAY 24: INSPECTION BY WOUND CONSULTANT

Wound healing successfully.
 Wound area was much smaller.

T: 80% red
I: No and less pain
M: Very moist
E: Scab formation, dry

Administration: continue current regime.

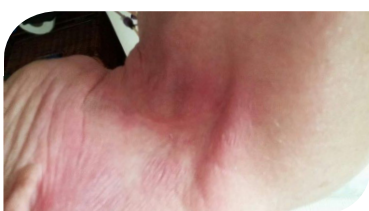


DAY 31: INSPECTION BY WOUND CONSULTANT

Moisture in the wound reducing.

T: 100% red
I: None, no pain, itchiness
M: Almost dry
E: Dry

Administration: White islands treated with Flaminal® Hydro and remaining skin with Flamigel®



DAY 49: INSPECTION BY WOUND CONSULTANT

Wound closed.

CONCLUSION: Recovery of the wound caused by radiation damage was successful with Flamigel® and Flaminal®. The patient experienced no pain when the dressing was changed.

INDICATIONS: Flamigel® is indicated as a treatment of superficial burns, including those caused by radiotherapy, as well as for the treatment of minor wounds and superficial open wounds. Flaminal® Hydro is indicated to be used on slightly to moderately exuding wounds.

References:

1. Censabella S. et al. Efficacy of a hydroactive colloid gel versus historical controls for the prevention of radiotherapy-induced moist desquamation in breast cancer patients. Eur J Oncol Nurs. 2017 Aug; 29:1-7.
2. Censabella S. et al. Retrospective study of radiotherapy-induced skin reactions in breast cancer patients; reduced incidence of moist desquamation with a hydroactive colloid gel versus dexpanthenol. Eur J Oncol Nurs. 2014 Oct; 18(5):499-504.
3. Van der Plas DL. et al. Treatment of recalcitrant wounds of diverse etiology with a new hydroactive gel. Wounds, 2009 Sep; 21(9):243-8.
4. Thomas, S. Wound management and dressings. The pharmaceutical press London. 1990 Ch.2: functions of wound dressing, p9-19.
5. Data on file. Tests with regards to absorbency and cooling. 2019

© Registered Trademark. Flamigel®, Flaminal® Hydro are the registered trademarks of Flen Health SA.

EBOS Code	Description	UOM
AS09010	Flamigel 50g	Each



FOR MORE INFORMATION CONTACT YOUR ACCOUNT MANAGER
 ON **FREEPHONE 1800 269 534** OR VISIT www.eboshealthcare.com.au

ESSENTIAL TO HEALTH